CLINICAL REPORT

# Ultrasound-Guided Cryoablation of a Traumatic Hip Disarticulation Neuroma

Ryan R. Ramsook, MD; David Spinner, DO

*Department of Rehabilitation Medicine, Icahn School of Medicine at Mount Sinai, New York, New York, U.S.A.*

■ **Abstract**

*Objective:* Traumatic amputation at the pelvic level is a rare procedure with few studies addressing long-term complications. Painful neuroma formation may form at the site of nerve transection and cause significant impairments in daily living. Ultrasound-guided cryoablation therapy has grown in popularity and should be considered in patients with painful neuromas. This is a case report of complete pain relief in a patient with rare traumatic hip disarticulation with neuroma formation, treated with ultrasound-guided cryoablation. The patient gave consent for publication.

*Design:* Single case report.

*Setting:* Mount Sinai Medical Center.

*Patient:* A 57-year-old man with traumatic hip disarticulation over 30 years ago with a 10-year history of severe residual limb pain from neuroma formation.

*Interventions:* Ultrasound-guided cryoablative injection therapy.

*Outcome Measures:* Pain reduction.

*Results:* Ultrasound-guided cryoablation of a traumatic hip disarticulation neuroma resulting in complete pain relief and improved functionality and independence.

*Conclusions:* This case illustrates a rare incidence of painful neuroma formation in a patient with traumatic hip disarticulation. Cryoablation with ultrasound guidance resulted in resolution of all pain. We report, to the best of our knowledge, the first occasion of an ultrasound-guided cryoablation resulting in complete pain relief in a traumatic hip disarticulation neuroma. ■

**Key Words:** cryoablation, traumatic hip disarticulation, ultrasound, amputation, neuroma

Hip disarticulations are a relatively uncommon procedure. It is thought that the incidence of this particular procedure accounts for 0.5–3.0% of all amputations.[1,2] Even then, the majority of these patients have either advanced malignancy or vascular impairment with prior failed leg-sparing procedures.[3,4] While the least common lower extremity amputation is transpelvic, traumatic hip disarticulations have been mostly studied during times of war.[5] These patients tend to be young and healthy. During the Iran–Iraq war (1980–1988), there were 20,801 veterans with amputations; of those, 84 had either a hip disarticulation or transpelvic amputation.[5] While there are limited studies highlighting the effect of these amputations on functional and social outcomes, there are scant data documenting complications including neuroma formation.[4,6,7]

Neuromas arise from nerves' ability to regenerate after an injury. Occurring after the transection of a nerve, neuromas are disorganized neuronal tissue that leads to a bulbous thickened end. Neuromas have branching Schwann cells and growing axons intertwined with scar tissue.[8] Their unmyelinated nerve endings are proposed to induce repeated misfiring through the upregulation of ion channels and receptors, resulting in pain.[9,10] Typically, neuromas develop 6 to 10 weeks after trauma, with most presenting 1 to 12 months after

Address correspondence and reprint requests to: Ryan R. Ramsook, MD, Icahn School of Medicine at Mount Sinai–Rehabilitation, One Gustave L. Levy Place, New York, NY 10029, U.S.A. E-mail: ramsook@gmail.com.

Submitted: January 18, 2016; Revised August 11, 2016; Revision accepted: October 3, 2016

DOI. 10.1111/papr.12534

injury.[11] In amputees, if the neuroma is large and located close to the skin surface, small amounts of pressure, traction, or irritation can lead to severe pain. The hyperalgesia and allodynia can prevent utilization of an otherwise properly fitting prosthesis, which can lead to impaired activities of daily living and propagate the pain syndrome.

Percutaneous interventional management procedures have been used for the treatment of neuromas.[12] Injections of neurolytic agents, steroids, radiofrequency ablation, and cryotherapy with image guidance, such as ultrasound, have resulted in favorable results with fewer complications.[13] Cryotherapy in particular had first been used in the 1970s by Lloyd et al.[14] for the treatment of pain and has continued to be used for numerous pain generators since then. The use of repetitive freeze cycles causes axonal degeneration while avoiding the perineurium and epineurium, which allows for subsequent axonal regeneration.[15] This regeneration may intuitively cause return of painful symptoms; however, neuroplastic remodeling may play a part in sustained pain relief.[15] While never before documented in a hip disarticulated patient, ultrasound-guided cryotherapy of residual limb neuromas in a pilot study showed the potential for a minimally invasive means for which to deal with painful neuromas after amputation.[16]

## CASE REPORT

A 57-year-old man with a past medical history of right hip disarticulation in 1978 presented to Mount Sinai Medical Center for evaluation and management of right residual limb pain. He endorsed a 10-year history of excruciating right-side residual limb pain refractory to medication management (Figures 1–4).

**Figure 1.** Residual limb after traumatic hip disarticulation highlighting severe area of allodynia.

**Figure 2.** Ultrasound probe with cryoablation needle positioned in an in-plane technique.

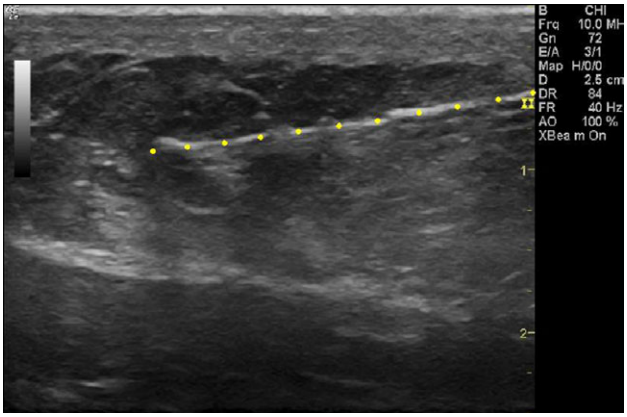


**Figure 3.** Cryoablation needle with ultrasound monitoring of distal ice ball formation.

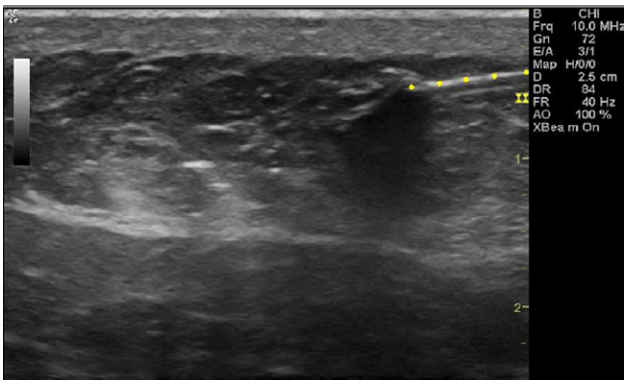


**Figure 4.** Cryoablation needle with ultrasound monitoring of proximal ice ball formation.

The patient described the pain as 10/10, intermittent, and knife-like in nature. There was also severe allodynia of the residual limb, which was minimally relieved with running cool or warm water over the amputation site. Prior to the onset of his severe pain 10 years ago, he was able to ambulate with the use of a hip disarticulation

prosthesis. He also had a new prosthesis made; however, he was unable to use it because it exacerbated his pain. He subsequently relied on bilateral crutches and a wheelchair for mobility.

Physical examination revealed a right hip disarticulation residual limb with well-healed skin graft sites. While there were no signs of erythema, pressure wounds, or infection, he had substantial allodynia over a palm-sized area on the residual limb. Ultrasound examination revealed right-sided residual limb neuroma, approximately 5 × 5 mm, for which an ultrasound-guided diagnostic nerve block was suggested. Given the patient's history of blast injury, trauma, hemipelvectomy, and graft surgery, it was difficult to define which peripheral nerve had been involved. That being said, his history, symptoms, and examination results were all consistent with a neuropathic etiology. The anatomy, however, did not allow for tracing of a focal nerve proximally, rendering further determination of the nerve origin impossible. Using ultrasound guidance, the neuroma was visualized and 5 mL of bupivacaine was injected. He tolerated the treatment well and noted immediate pain relief lasting about 12 hours. With excellent results from the diagnostic block, the patient was scheduled for cryotherapy.

One week later, the patient returned for cryoablation of the residual limb neuroma under ultrasound guidance. Using a 12-mHz linear array transducer, the probe was directed towards the point of maximal tenderness. After local anesthesia with 1% lidocaine, an iovera 155 Smart Tip cryoablation probe (Myoscience Inc., Fremont, CA, USA) was utilized for an in-plane approach. Visualization of the needle tip towards the neuroma ensured proper depth and placement. Four freezing cycles were completed in an axial plane from inferior to superior. This was performed in the entire area of pain, to ensure as complete coverage as possible. The patient tolerated the procedure well without any complications. The following day the patient was noted to have complete resolution of symptoms. He was also able to walk pain free with his prosthesis, which he had been unable to do for the past 10 years. The patient remains doing well, and 6 months postprocedure the patient maintained resolution of symptoms without any complications or adverse events. The patient gave consent for publication.

## DISCUSSION

To the best of our knowledge, this is the first case report in the literature of cryoablation therapy for the treatment of a painful neuroma after traumatic hip disarticulation. This case highlights the safety and efficacious use of sonographically guided cryotherapy for neuroma in a particularly uncommon amputation.

Traumatic hip disarticulation is a relatively uncommon amputation. Most transpelvic amputations are performed secondary to malignancy or vascular problems; however, the rarity of traumatic etiology leads to few studies addressing this subtype of amputations. Neuroma formation can occur any time a nerve is transected; however, not all neuromas are painful. The literature on painful neuromas in traumatic hip disarticulation is severely lacking. Management and treatment options consequently are based on studies of neuromas in other forms of amputation.

Interventional management options of painful neuromas have continued to grow in popularity due to excellent results with relatively low complication rates as compared to surgical options. Phenol injections have traditionally been used; however, there has been a rise in the number of cyroablative procedures for neuromas. Coupled with ultrasound guidance, cryotherapy has become a more commonly utilized treatment option. With sonographic guidance, the needle placement can be confirmed and complications minimized.

Our patient had an uncommon transpelvic amputation. As such, data concerning complications and their management are lacking. Neuroma treatment with cryoablation in the traumatic hip disarticulation population has not been reported in the literature. Complete resolution of pain without complications in our patient showed that our treatment option should be considered in similar patient populations. Improvement in pain, functionality, independence, and social well-being highlights the importance of our interventional treatment plan. After failed conservative management, a diagnostic nerve block should be performed to confirm the neuroma being the gain generator. After a successful nerve block, ultrasound-guided cryotherapy for painful neuroma in a patient with hip disarticulation may be considered.

## CONCLUSION

Traumatic hip disarticulation is a relatively uncommon amputation. Complications from the procedure include neuroma formation, which may result in severe, debilitating pain. We present, to the best of our knowledge, the first confirmed case of a successful ultrasound-guided cryoablative injection therapy in a patient with

traumatic hip disarticulation. After failed medication management and positive diagnostic nerve block, this interventional management option may be considered for pain relief and to restore functionality and independence.

## CONFLICT OF INTEREST

The authors have no conflicts of interest.

## REFERENCES

1. Dillingham TR, Pezzin LE, MacKenzie EJ. Limb amputation and limb deficiency: epidemiology and recent trends in the United States. *South Med J*. 2002;95:875–883.

2. Wakelin SJ, Oliver CW, Kaufman MH. Hip disarticulation: the evolution of a surgical technique. *Injury*. 2004;35:299–308.

3. Denes Z, Till A. Rehabilitation of patients after hip disarticulation. *Arch Orthop Trauma Surg*. 1997;116:498–499.

4. Unruh T, Fisher DF Jr, Unruh TA, et al. Hip disarticulation: an 11-year experience. *Arch Surg*. 1990;125:791–793.

5. Ebrahimzadeh MH, Kachooei AR, Soroush MR, et al. Long-term clinical outcomes of war-related hip disarticulation and transpelvic amputation. *J Bone Joint Surg Am*. 2013;114:1–6.

6. Yari P, Dijkstra U. Functional outcome of hip disarticulation and hemipelvectomy: a cross-sectional national descriptive study in the Netherlands. *Clin Rehabil*. 2008;22:1127–1133.

7. Furtado S, Grimer RJ, Cool P. Physical functioning, pain and quality of life after amputation for musculoskeletal tumours: a national survey. *Bone Joint J*. 2015;97B:1284–1290.

8. Clarke C, Lindsay DR, Pyati S. Residual limb pain is not a diagnosis: a proposed algorithm to classify postamputation pain. *Clin J Pain*. 2013;29:551–562.

9. White J. Pain after amputation and its treatment. *JAMA*. 1944;124:6.

10. Lai J, Porreca F, Hunter JC, et al. Voltage-gated sodium channels and hyperalgesia. *Annu Rev Pharmacol Toxicol*. 2004;44:371–397.

11. Henrot P, Stines J, Walter F, et al. Imaging of the painful lower limb stump. *Radiographics*. 2000;20:S219–S235.

12. Rajput K, Reddy S, Shankar H. Painful neuromas. *Clin J Pain*. 2012;28:639–645.

13. Masala S, Fanucci E, Ronconi P, et al. Treatment of intermetatarsal neuromas with alcohol injection under US guide. *Radiol Med*. 2001;102:370–373.

14. Lloyd JW, Barnard JD, Glynn CJ. Cryoanalgesia: a new approach to pain relief. *Lancet*. 1976;2:932–934.

15. Ramachandran VS, Rogers-Ramachandran D. Phantom limbs and neural plasticity. *Arch Neurol*. 2000;57:317–320.

16. Neumann V, O'Connor RJ, Bush D. Cryoprobe treatment: an alternative to phenol injections for painful neuromas after amputation. *Am J Roentgenol*. 2008;191:W313.